

## **Clinical assessment and outcomes of Management of Urinary Hydatid Cyst**

**Asaad H. Imran<sup>1\*</sup>, Asif Zain Nuh<sup>1</sup>**

Urology Department, Beni-Suef University, Faculty of Medicine, Beni Suef University, Beni Suef, Egypt

\*Corresponding Author ,

**Original Article**

---

### **ABSTRACT**

*Background:*

Urinary hydatid cyst is not uncommon in Egypt either isolated or in association with other organs'hydatid cyst in the same patient. **Objective:** To criticize the diagnosis and the treatment options for urinary hydatid cyst performed in the urological department at Beni Suef University Hospital.

**Patients and Methods:** A total of 22 patients with urinary hydatid cysts who were treated in the Urology Department , Beni Suef University Hospital, were enrolled in this study during the period from December 2007 to October 2014. Treating options varies according to the size, number and the site of the cysts; these include total nephrectomy, partial nephrectomy and cyst excision for the renal hydatid, with one case treated by pyeloplasty for renal pelvic hydatid cyst. Also cyst excision was done for one patient with paravesical hydatid cyst.

**Results:** Only 21 patients were treated surgically;Total nephrectomy performed in (7cases), partial nephrectomy in 9 cases, and4 cases with renal hydatid cyst were treated by cyst excision after instillation of a scolicial agent, recurrence occurred in one case after one year follow up that necessitated total nephrectomy. Pyeloplasty done in one patient with renal pelvic hydatid cyst and it was uneventful.

**Conclusion:** Hydatid cyst of the urinary system is not uncommon in Egypt, total nephrectomy, partial nephrectomy and cyst excision are the main treatment options.Lower rate of complications were reported during follow-up period

**Keywords:** Urinary Hydatid Cyst, pathogenesis, epidemiology, treatment options, nephrectomy total, partial, excision of cyst

---

## 1. INTRODUCTION

Hydatid cyst of the urinary system is not uncommon in Egypt. Kidney's hydatid cysts contribute for almost two to three percent of all cases with hydatid diseases cases of hydatid disease.(1-2).

Hydatid cysts of the urinary tract can stay asymptomatic for years before being detected since they lack unique pathognomonic characteristics, until the cyst ruptures in the collecting urinary system, where such patient usually presented with hydatiduria and acute renal colic. (3-4) The cyst usually start in the cortex of the kidney and gradually enlarges and may be rupture into a calyx.(5)

Echinococcus granulosus, a cestode, causes hydatid cyst disease. The larval stage of the tapeworm Echinococcus granulosus causes a global zoonosis. The adult worm can be found in the small intestine of the definit host, which is a domestic dog usually. The eggs present in the host's intestines and are passed by the feces. Intermediate hosts, one of whom is a human, can come into contact with the definit host or ingest infected food or water. During digestion in the duodenum, the egg's protective cover is lost. The parasitic embryo then passes through the intestinal wall and into the lymphatic or portal vein system; the liver is the first organ to be infected and is considered the body's first line of protection. (6)

The provisional diagnosis of urinary hydatid cyst is usually done radiologically. The sonographic finding in hydatid cyst include well-defined anechoic lesions. When the daughter cyst is not visible, it is so difficult to be differentiated from simple serous or hemorrhagic cyst. Among the CT-scan findings for renal hydatid a thick-walled or calcified cyst, a single-celled cyst with an exfoliated membrane, a multicellular cyst with mixed internal density, and daughter cysts with a density less than that of the maternal matrix. (6-7)

## 2. PATIENTS and METHODS

A total of 22 patients with urinary hydatid cysts who were treated in the Urology Department, Beni Suef University Hospital, were enrolled in our study in the period from December 2007 to October 2014. Every patient was submitted to history, physical examination, GUE, ultra-sound, and CT scan were done . Despite the availability of the ultra-sound CT scan or IVP study, the preoperative diagnosis was challenging, only 16 cases(72.7%) were diagnosed as hydatid cyst while 6 (27.3%) cases were difficult to reach a precise pre-operative diagnosis.

And were approved intraoperatively.

Treating options varies according to the characteristics of the cyst which are number of cysts, site and size . For renal hydatid, options include total nephrectomy, partial nephrectomy, cyst excision for the renal hydatid after injection of a scolicial agent (savilon). One case was treated by pyeloplasty for renal pelvis hydatid cyst (Andersen Heinz operation). Renal surgeries were done under general anesthesia with the patients in flank position, and a flank incision was done, and dissection of muscle layers to reach the kidney. Rib resection was done in upper pole cysts(8 cases). Pedicle clamp was needed in all case of partial nephrectomy.

For the paravesical hydatid cyst, cyst excision was done after injection of a scolicial agent

#### ***Statistical methodology:***

All statistical procedures and analyses were performed using the Statistical package for social science version 25. Statistical tests applied according to the variable types.

### **3. RESULTS**

From 22 patients, 17 patients (77.2%) were males and 5(22.8%) were females with a male to female ratio of 3.4 to one, (**Figure 1**), Age of the patients ranged 16-65 years with mean of (mean  $34.3 \pm 6.7$ ) years. From all cases, 2 patients (8.6%) presented with hydatiduria but one patient was completely normal by abdominal ultra-sound and CT scan. In 19 patients, the hydatid cyst was in the renal parenchyma (86.36%), one patient (4.54%) in the renal pelvis, one patient (4.54%) presented with para vesical hydatid cyst and one patient(4.54%) presented with just hydatiduria (normal both kidneys by abdominal ultrasound and CT scan). In 16 patients (80%), the left kidney was affected and 6 cases (20%) in the right kidney. In 14 patients(60%), the lower pole was affected and 8(40%) in the upper pole.

Among the 22 patients with renal hydatid cysts, only 21 patients operated on, while one patient had only hydatid urea and was not operated. The remaining 21 operations, were total nephrectomy in 7 cases of them 5 cases had a large hydatid cyst of (>7cm) or multiple hydatid cysts in nonfunctioning kidney, another case with unsettled diagnosis and thought to be large renal stone in nonfunctioning kidney by IVP, on operation appeared to have large hydatid cyst and total nephrectomy was done, another total nephrectomy performed in one case who had recurrence after one year of follow up that necessitated total nephrectomy,. The peri-operative period passed uneventfully.

Partial nephrectomy performed in 9 cases, of them 5 patients with renal hydatid cyst of <7cm and one of these 5 cases had urinary fistula which was healed after one month follow up. The other 4 cases treated with partial nephrectomy were unsettled diagnosis and their hydatid cysts were less than 7 cm and treated with partial nephrectomy. Cyst excision after instillation of a scolicial agent performed in 4 cases, with single renal hydatid cyst. Of them one patient with paravesical hydatid cyst and another case planned for FNA for reaching the diagnosis but developed cyst infection with no anaphylactic reaction and treated by cyst excision. Pyeloplasty done in one patient with renal pelvis hydatid cyst, This case was discovered intra-operatively when the renal pelvis is opened to do pyeloplasty, a cyst filled the pelvis which completely inoculated. Also there was no post-operative complications. It is worth mentioning that three cases were considered as solid non enhanced renal tumor, 2 cases as complicated cyst ( CT scan showed Posiniac classification range from 2 to 3). All these findings are demonstrated in (Tables 1,2 , 3 and Figures 1& 2) All cases were proved by histopathological study as a hydatid cyst.

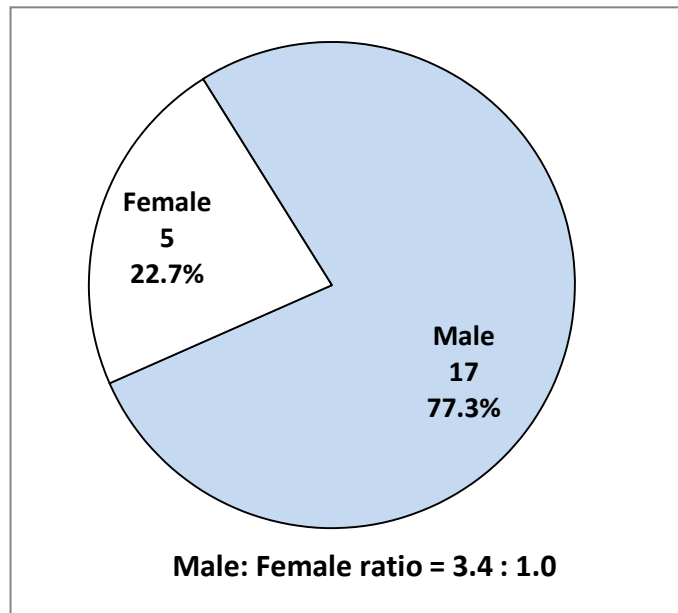


Figure 1. Gender distribution of the studied group

**Table 1. Side and site of hydatid cyst (N = 22)**

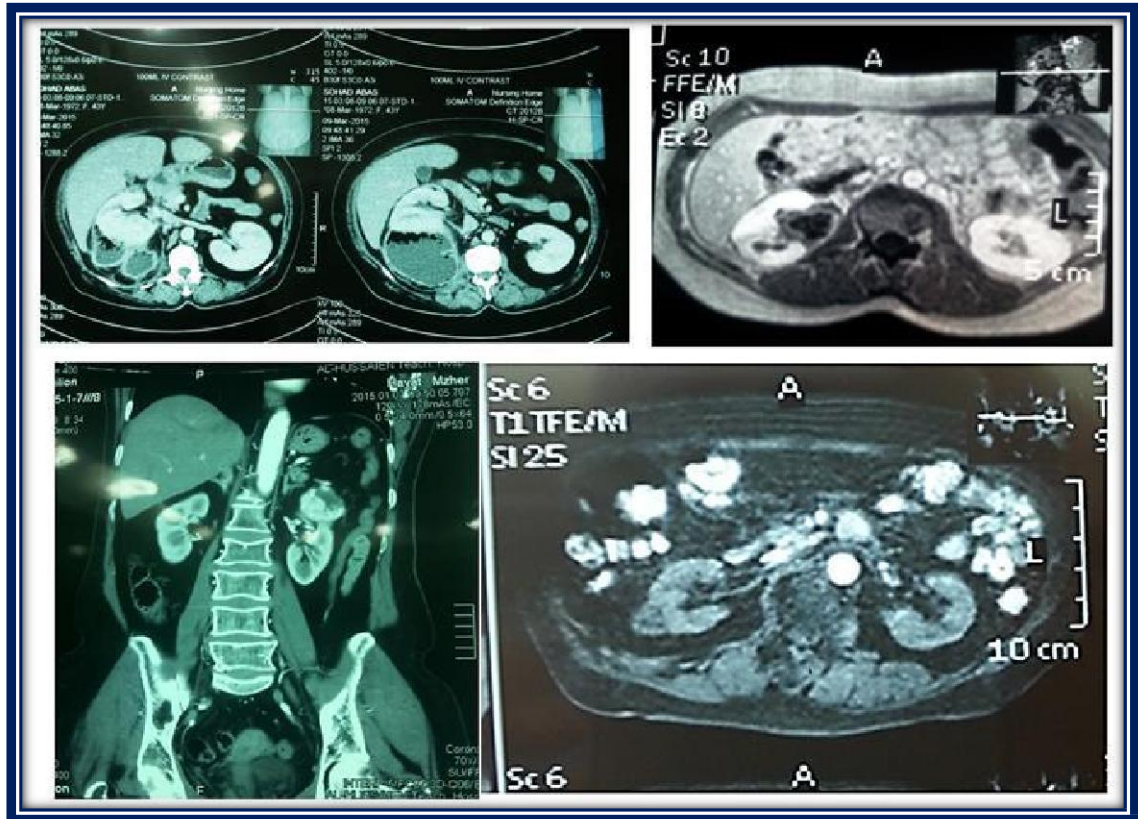
Variable	No.	%
Side		
Left kidney	16	72.7
Right	6	27.3
Site		
Renal parenchyma	19	86.4
Renal pelvis	1	4.5
Para-vesical	1	4.5
Undetrmined\ just hydatiurea	1	4.5
Affected pole		
Lower pole	14	63.6
Upper pole	8	36.4

**Table 2. Type of surgery performed for treatment of urinary hydatid cyst (N = 22)**

Type of surgery	No.	%
Total nephrectomy	7	31.8
Partial nephrectomy	9	40.9
Cyst excision after ,	4	18.3
Pyeloplasty	1	4.5
Non-operated	1	4.5
Total	22	100.0

**Table 3. Complications developed among the studied group (N = 22)**

Complication	No.	%
None	19	86.4
Urinary fistula	1	4.5
Recurrence after one year	1	4.5
Cyst infection with no anaphylactic reaction	1	4.5
Total	22	100.0



#### 4. DISCUSSION

Hydatid cyst is worldwide disease , Egypt is one of the endemic areas and there is good opportunity for building considerable surgical experience and search.

In our study we found that the left kidney was more affected(80.%) while R. Yavuz et al found the right side was more affected. (8)

Pre –operative diagnosis of renal hydatid cyst some time is so difficult because it may resemble a simple renal cyst, solid mass or even look like a stone which cannot be differentiated even by CT scan or MRI studies. The only pathognomonic symptom of the disease is gelatinous echinococcal material (grape skins, young / daughter cysts) in the urine, caused by a cyst rupture in the collection system. (9-10).

Ahmet et al showed that renal hydatid is a diagnostic dilemma when presented with nonspecific heterogeneous appearance. (11).Therefore any case of renal cyst or mass, The echinococcal cyst should be considered in the differential diagnosis. and managed carefully especially in endemic

area like Egypt.

In the present study all patients with renal hydatid cyst were treated surgically; (nephrectomy, partial nephrectomy or cyst excision) and there was no place for percutaneous drainage which was done by Goel et al. who reported this option as a safe method with no or minimal renal loss, less morbidity and short duration of in-hospital stay, and they also documented that percutaneous aspiration carries high risk of anaphylactic shock and dissemination. (12)

Although we used albendazole as a routine post –operatively measure but we did not use it as a therapy for renal hydatid, and there was no place for medical treatment by albendazole, mebendazole or praziquantil in our study which were used in some studies that reported unsatisfactory results.(13-14)

In our study, from 20 patients with renal hydatid cyst, only 7 patients(35%) treated by total nephrectomy, while Benchekroun et al reported the use of nephrectomy at 40%, and Sengor and colleagues performed nephrectomies in 36.3% for management of renal hydatid disease. (15)

In our study, partial nephrectomy done in 5 cases (25%) with one complication in one case, and this finding consistent with other previously published literatures ; like R. Yavuz et al. found that partial nephrectomy done in 10% of the surgically managed renal hydatid. (8)

In our study we did cyst excision and marsupialization in 7 cases(35%) and it is comparable with other studies like R. Yavuz et al showed that cyst excision done in 23% of the surgically managed renal hydatid. (8)

## **5. CONCLUSIONS:**

Hydatid cyst of urinary system is not uncommon in Egypt. and the urosurgeon should be familiar with the treating options that provide the best results in term of preserving the renal tissues and preventing recurrence. Additionally, hydatid cyst should be kept in mind as one of the important differential diagnosis in any case presented with renal cyst or mass. We suggested a large-scale multicenter study for longer duration to address further the size of the problem and reach these goals



**Ethical Approval:** Data collected in accordance with World Medical Association (WMA) declaration of Helsinki, 2013 for the ethical principles for medical researches involving human subjects. Privacy of the patients was ascertained, all names and identification records were coded and the data kept confidentially in a password protected computerized files . Signed informed consent obtained from each participant before surgery and prior to recruitment in the study.

**Funding:** none, self- funded by the author

**Conflict of Interest:** None declared by the author

**Acknowledgment:**

Author would like to thank all participants of the study , hoping they have a good , safe and healthy life. Gratitude to all staff of the operation room and department of urosurgery at Beni Suef University Hospital, for their cooperation and help to make this work successful.

**References**

1. Buckley RJ, Smith S, Herschorn S, et al. Echinococcal disease of the kidney presenting as a renal filling defect. *J Urol.* 1985;133:660-661.
2. Tscholl R, Ausfeld R. Renal reimplantation (orthotopic autotransplantation) for echinococcosis of the kidney. *J Urol.* 1985;133:456-457.
3. Gogus O, Beduk Y, Topukcu Z. Renal hydatid disease. *BrJ Urol* 1991;68:480-489.
4. Unsal A et al. An unusual causes of renal colic:hydatiduria.*Int J Urol* 2001;8:319-321.
5. Refaat kamel, John Lumley. *Tropical surgery: renal hydatid disease.*1<sup>st</sup> ed.2004;1206.
6. Pedrosa I, et al. hydatid disease: radiologic and pathologic features and complication. *Radiographics* 2000;20:795-817.
7. Turgut A T, Altin L, Topcu S et al. Unusual imaging characteristics of complicated hydatid disease.*Eur JRadiol* 2007;63:84-93.
8. R.Yavuz et al. Hydatid disease of the kidney: A retrospective review of 13 cases
9. Poullos C. Echinococcal disease of the urinary tract: review of the management of 7

- cases. *J Urol.* 1991;145:924-927.
10. Aragona F, Di Candio G, Serretta V, Fiorentini L. Renal hydatid disease: report of 9 cases and discussion of urologic diagnostic procedures. *Urol Radiol.* 1984;6:182-186.
  11. Ahmet, et al. Multitechnique evaluation of renal hydatid disease. *AJR* 2009; 192:462-467.
  12. Goel MC, Agarwal MR, Misra A. Percutaneous drainage of renal hydatid cyst: early results and follow-up. *Br J Urol.* 1995;75:724-728.
  13. Bryceson AD, Cowie AG, Macleod C, et al. Experience with mebendazole in the treatment of inoperable hydatid disease in England. *Trans R Soc Trop Med Hyg.* 1982;76:510-518.
  14. Bekhti A, Nizet M, Capron M, et al. Chemotherapy of human hydatid disease with mebendazole. *Acta Gastroenterol Belg.* 1980;43:48-65.
  15. Benchekroun A, Lackhar A, Soumana A, et al. Hydatid cyst of the kidney: report of 45 cases. *Ann Urol (Paris).* 1999;33:19-24.