

Correlation of Inter-Ictal EEG Localization with Semiology and MRI in Symptomatic Focal Epilepsies

Sawsan AlBaazi^{1*}, Akram Al-Mahdawi²

*Corresponding Author , contact email : sunflower_sma@yahoo.com

Original Article

Summary

Analysis of seizure semiology may provide a valuable information on the seizure onset zone and can be determined by history or video records of ictal event. Seizure semiology as a localizing tool could have some limitations and pitfall including inter-rater variability, therefore, we tried to assess the accuracy of basic level inter-ictal EEG in comparison to MRI to identify epileptiform changes and localization of epileptogenic lesions in less time and cost. Hence, A cross-sectional study conducted at the Epilepsy Clinic in Baghdad Teaching Hospital / Medical City during 2017 – 2018, included 70 patients referred for evaluation of recurrent seizures. We found that Basic level inter-ictal EEG with partial sleep deprivation can be used in localization and tracking of epileptogenic pathways, and the concept of being discordant from semiology should have a crucial attention, as previously suggested that the irritative zone correlate more accurately with epileptogenic zone.

Keywords: Seizure, Focal Epilepsies, Inter-Ictal EEG, Semiology, MRI

1. INTRODUCTION

An electroencephalogram (EEG) record, is that picture of brain function through which a brain lesion, as a painter; can show its drawings by means of its type, location and possibly rate of progression. Yet, should an electro-encephalographer has rules in order to read and understand these drawings. In addition to magnetic resonance imaging (MRI), EEG localization is very important tool for determining the possible etiology in cases of “lesional epilepsies” because what we see in “Brain MRI is just the tip of the iceberg”. (1) Most focal brain lesions as “glial brain tumors, abscesses, cysts and scars of previous insults” are deficient in neuronal tissues, that can't induce seizure manifestations, but they can induce changes in their surrounding environment. These changes may occur in the borders of the lesion or in similar areas of contralateral hemisphere in the form of “ischaemia, oedema, local neuronal injuries (as in synapses), electrical and biochemical changes” which were proved by histopathological studies. (2) The epileptogenic zone is the zone that contains an epileptogenic lesion, symptomatogenic areas, irritative zone and seizure onset areas. Intersection of these areas as detected by clinical, neuroimaging, electrophysiological and sometimes neuropsychological means, may increase the possibility of correct detection of the dysfunctional brain region. (1). Correlation between ictal EEG and epileptogenic lesions using Video EEG monitoring is a widely used method for localization. However, seizures not necessarily arise from the lesion site or its boundary, as there may be remote areas from which seizures may arise. (1,3). This concept had been extensively studied and further confirmed by an increasing rate of success of epilepsy surgeries when considering areas demonstrating inter-ictal EDs in their excision. (4)

Inter-ictal EEG became more reliable to assess epileptogenic zone, however; using long term V. EEG to assess inter-ictal EDs is time consuming and expensive. (5). On the other hand, timing of routine inter-ictal EEG recording may be extra short for accurate localization. However, if extended to involve sleeping time, especially if the patient was sleep deprived; may increase sensitivity to detect inter-ictal EDs. The question is that to what extent routine inter-ictal EEG can be used as a reliable localization tool?. Focal epileptic seizures are proposed to originate within networks in one cerebral lobe, may be focal (when epileptogenic focus involves one hemispheric lobe as frontal, temporal, parietal or occipital), multilobar (when epileptogenic focus covering two or more contiguous unilateral lobes, e.g.

frontal-temporal, temporal-parietal and so on) or multifocal (refers to more than one, independent, non-adjacent epileptogenic focus) (6-10). Focal seizures may originate from subcortical structures. There may be more than one network and thereby more than one seizure type (9,11). Focal epilepsies may be idiopathic, symptomatic or probably symptomatic (cryptogenic). (12,13) . Symptomatic epilepsy of an acquired or genetic cause, associated with gross anatomic or pathologic abnormalities, and/or clinical features, indicative of underlying disease or condition. Developmental and congenital disorders that are associated with cerebral pathologic changes, whether genetic or acquired in origin are included in this category. Also included are single gene and other genetic disorders in which epilepsy is only one feature of a broader phenotype with other cerebral or systemic effects (14,15). There are numerous causes of symptomatic epilepsies and an individual may have more than one etiology as in cases of combination of genetic factors and structural abnormalities, of which genetic predisposition may lower an individual's threshold to have epileptic seizures induced by structural abnormality. (10,15). The etiology of symptomatic epilepsies could be ; benign and malignant tumors , viral or other infectious and parasitic disease, cerebrovascular disorders, malformations of cortical development, genetically determined brain and metabolic disorders, trauma and other injuries. Lesions behave differently with regard to their consistency, aggressiveness and size. (16-20).

Seizure Semiology describes the subjective and objective signs and symptoms of a seizure. These signs can be used to classify seizures and may have a localizing and lateralizing value about the source of the seizures. The clinical manifestations of a seizure define the symptomatogenic zone (the area of cortex when activated by the epileptic discharge or by intracranial electrical stimulation can produce the clinical symptoms of the epileptic seizure) (21). Therefore, the analysis of seizure semiology may provide a valuable information on the seizure onset zone and can be determined by history or video records of ictal event (1,22).

Seizure semiology as a localizing tool could have the following limitations; significant inter-rater variability, ictal symptoms could originate from distant and silent areas and manifest only after their spreading (1), it may not always permit differentiation between focal and generalized epilepsies (23,24). The interictal EEG is an electroencephalographic recording that does not contain seizures or ictal manifestations and is therefore obtained in between clinical attacks. It is the most frequent recording type used in clinical practice (25,26).

Utility of interictal EEG on skilled hands, can provide vital information that aids in diagnosis and management of epileptic patients and enhances our understanding of their condition, it is useful to confirm a clinical diagnosis of epilepsy, exclude certain epilepsy syndromes, classify epilepsy type and syndrome, detect or confirm the existence of photosensitivity, detect antiepileptic drug intoxication, detect potential epileptogenic cerebral lesions, and help to assess patients for epilepsy surgery (5,26). However it couldn't be a reliable tool with some limitations such as absent with definite epilepsy in about 20% of cases and short duration of recording or single EEG record (27-29), misleading, Bilateral or multifocal widespread. There are different types of inter-ictal epileptiform discharges. (30-32). EEG features that point to symptomatic focal epilepsy include ; Intermittent focal slowing, variability of localization on different EEG recording, Polymorphic slow waves and EDs do not react to external stimuli, presence of unusual fast activity, spikes with or without focal slowing related to lesional topography, rarely SBS and background EEG abnormalities. There are two levels of EEG recording (33-35); basic and advanced. Sleep deprivation, sleep recordings, hyperventilation and intermittent photic stimulation (IPS) are widely used methods for increasing the chance of detecting IEDs. Regarding Neuroimaging in symptomatic epilepsy, MRI is a crucial for the diagnosis and treatment of symptomatic epileptic patients. MRI allows the determination of the nature of the lesion and whether it is progressive or static Nonetheless, not all MRI abnormalities can cause seizures and not all seizures arise from well identified structural cerebral abnormalities (36-40).

2. PATIENTS and METHODS

A cross-sectional study conducted at the Epilepsy Clinic in Baghdad Teaching Hospital / Medical City during 2017 – 2018, included 70 patients referred for evaluation of recurrent seizures. They comprised of 37 females and 33 males with an age range between 4 and 66 years. Symptomatic focal epilepsy was their final diagnosis according to ILAE classification 2001 (12). The diagnosis was made by clinical history and examination, routine brain MRI (1-1.5 Tesla with epilepsy protocol) (41) and high resolution MRI (3 Tesla) when needed and were reviewed and classified by specialist radiologists. Biochemical investigations in addition to neuropsychological assessment were done whenever needed.

Inclusion criteria

1. Patients with well-defined brain MRI lesion.
2. Classified seizure phenotypes according to ILAE 2017 (8)
3. Inter-ictal EEG with well-defined focal EDs or no EDs.

Exclusion criteria

1. Previous history of epilepsy compatible with the diagnosis of IGE or benign focal epilepsy of childhood, not resolving till the time of arrival to the epilepsy clinic.
2. Brain MRI with diffused cerebral atrophy or widespread white matter lesions.
3. Inter-ictal EEG with exclusively generalized or multifocal EDs.
4. Patients with non-convulsive status epilepticus during the study of EEG.

Inter-ictal EEG:

All the patients were examined using Basic level (level 2) EEG. (35) Electrodes placement was according to 10-20 international system (41) using 29 channels (21 standards with the addition of 6 electrodes to cover the inferior temporal regions on each sides designated as F9, T9, P9 and F10, T10, P10 in addition to 2 EKG electrodes). Device setting met the ACNS guidelines (42) with inter-electrode impedances kept below 5 KOhms, low frequency filter at 1 Hz and high frequency filter at 35-70 Hz, voltage display (sensitivity) at 70 μ V (adjusted when needed) and paper speed at 30 mm/sec. EEG recording was extended for 60 minutes, involving an awake state with 2.5 minutes of eyes opening, 2.5 minutes of eyes closure, IPS, 3 minutes of hyperventilation and at least 20 minutes of sleep record. (42,43)

Provocation methods**a) Partial sleep deprivation**

All the patients were given appointments for having EEG examination to ensure that appropriate preparations were achieved. We asked them to change their sleeping schedule the night prior to the test, with decreasing their sleep hours by getting to bed 1-2 hours later and awakening 1-2 hours earlier than their routine sleep practice and stay awake till the time of examination. (15,44,45)

b) Hyperventilation

The patients were instructed to breathe deeply and quickly (deep breathing is more important) at a rate of 20 deep breaths/min for 3 minutes. Young children were

encouraged to hyper ventilate by asking them to blow on a brightly colored pinwheel or a balloon. (15,46).

c) Intermittent photic stimulation:

Applied while the patients awake, in dim light using a flash light of 1 joule intensity at a distance of 30 cm. IPS sensitivity was determined during eyes closure, eyes closed, and eyes opened states using a train of flash frequencies separated by 5 seconds duration for each 1– 2 – 8 – 10 – 15 – 18 – 20 – 25 – 40 – 50 – 60 Hz. If there was a generalized response at a certain frequency, then the train should be stopped and repeated in a descending order starting from 60 Hz to define the lower and upper threshold for the response. (43)

Identification of epileptic discharges

The EDs were identified according to the following criteria: (5)

1. The discharge should be paroxysmal and a peak amplitude greater than a threshold value based on the background IEEG.
2. The discharge typically shows an abrupt change in polarity occurring over several milliseconds resulting in a sharp contour or spikiness.
3. The duration should be less than 200 ms. Spikes last between 20 and 70 ms, and sharp waves last between 70 and 200 ms. Spikes or sharp waves are typically negative in polarity. The distinction is morphologic in nature, and there is no clinical reason to distinguish between them. The discharge must have a physiologic field, with the discharge recorded from more than one electrode and a voltage gradient should be present. Most spikes are followed by an after going slow wave ranging from 100-500 ms. (28). EEG was reviewed using longitudinal Bipolar and average referential montage with/without transverse Bipolar and Laplacian montages. (47,48) Activity involving multiple electrodes over multiple lobes of a single hemisphere having a 2:1 or greater amplitude predominance than that seen over the contralateral hemisphere, were termed lateralized. While activity maximal at a single electrode with no more than 2 contiguous electrodes within 80% to 100% of the maximal amplitude were referred to as localized. (49)The frequency of EDs were enumerated manually in terms of occurrence per 1 hour. (51,52). The frequency of EDs were enumerated manually in terms of occurrence per 1 hour. (50,51).

Seizure semiology

Patients' history was reviewed by specialist neurologists to determine ictal semiologic features supported by home video records when available. Seizures selection and localization were performed according to the following criteria: (24)

a) It has to be the first or one of the earlier components of the seizure for the purpose of having a reliable localizing value as later symptoms or signs are more likely to be due to ictal spread and may have only a lateralizing value.

b) Easy to be identified and classified with a high interrater reliability.

Statistical analysis

Data tabulation, input and coding was done by the use of IBM© SPSS©

(Statistical Package for the Social Sciences) Statistics Version 22. For descriptive statistics, percentage were applied. Chi-Square test was used for categorical data. Discrepancy and concordance rates were calculated using correlation (Spearman rank-correlation analysis (ρ)) and test of agreement (Cohen κ). Values of κ between 0.20–0.39 interpreted as minimal (mild) agreement. Positive values of ρ between 0.30–0.50 were considered as weak correlation.

3. RESULTS

The mean age of the patients was 26.56 ± 15.35 years (range 4-66 years). Of total sample, 32.9% were below 18 years. Males were 33 (47.1%), and females 37 (52.9%), and one fourth of the patients had family history of epilepsy 18 (25.7%) while 52 (74.3%) without. Of those who have family history of epilepsy, 10 (55.6%) have extra-lesional EDs and 8 (44.4%) with localized EDs. Most patients had their lesions located in their Temporal lobe 28 (40.0%), followed by Frontal 20 (28.6%), then Parieto-occipital lobes 12 (17.1%), and least with multilobar involvement 10 (14.3%) as shown in (Figure 1).

The two most common types of EEG abnormalities were exclusive EDs with 30 (42.86%), and EDs plus focal slowing 29 (41.43%), and least with normal EEG 6 (8.57%) and EDs plus others (Fast activity or PLED) 5 (7.14 %). (Figure 2). The main finding of the epileptiform discharges was a mean latency of 6.92 ± 10.51 minutes, and a mean frequency of 165.88 ± 262.80 per hour, which constituted of 41.10 ± 81.93 in wakefulness, 5.01 ± 12.79 evoked with hyperventilation, 2.40 ± 8.48 evoked by intermittent photic stimulation, and the majority was while the patients enter the NREM sleep (stage I and II) with

117.17±185.68 discharges (Table 1).

Table 2 illustrate a statistically significant association between interictal EEG and sites of epileptogenic lesion, and most frontal and temporal lobe lesions were localized to the lesional lobe, 10 (50.0%) and 16 (57.1%) respectively, while Parieto-occipital lesions had interictal EEG with extralesional abnormalities 8(66.7%) and the majority of multilobar lesion had their EEG abnormalities lateralized to the same side of the lesions 9 (90.0%). Classifying the lesions according to their types showed that most frequent lesions were tumors 20 (28.5%) from which meningioma and gliomas were 6 (30.0%) for each, then encephalomalacia following stroke/trauma 13 (18.6%), also hippocampal sclerosis was diagnosed in the same frequency of 13(18.5%), vascular malformation in 9 (12.8%), cysts in 8 (11.4 %), cortical malformations in 4 (5.7%) and CNS inflammation in 3 (4.3%) as demonstrated in (Table 3).

Interictal EEG localization of lesions regarding hippocampal sclerosis showed that it was localized in 6 (46.2%), extralesional with or without localization each 3 (23.1%), and 1 (1.4%) normal EEG results. Most meningiomas were localized 4 (66.7%). Glioma was localized in 3(50.0%) and extralesional in 3(50.0%). Majority of DNET lesions were localized. Gangliogliomas were either localized or extralesional.

Of the total 7 cavernous sinus lesions, 3(42.9%) were localized, 2(28.6%) were normal, and 1(14.3%) were either extralesional with or without localization. AVMs showed extralesional activities in 1(50.0%) and extralesional with localization with the other 1(50.0%). FCDs were either lateralized or extralesional. Tuber malformation showed localized activity. Focal pachygyria showed extralesional activity. Most encephalomalacia following stroke/trauma were lateralized to the side of lesions 8 (61.5%), two localized and two extralesional. CNS inflammation showed three different activities; localized, lateralized and extralesional. Cysts showed all types of EEG activities (Table 4). Semiologic localization of lesions regarding hippocampal sclerosis showed that the majority were localized 12 (92.3%) and 1 (7.7%) with one generalized result. Meningiomas were either localized 3 (50.0%) or generalized in the other 3 (50.0%). Gliomas were localized in 4 (66.6%), extralesional in 1 (16.6.0%), and generalized in 1 (16.6.0%). Majority of DNET lesions were localized. Gangliogliomas were either localized or extralesional.

Of the total 7 cavernous sinus lesions 4 (57.1%) were localized, 2 (28.6%) were

extralesional, and 1 (14.3%) was generalized. AVMs showed localized activities in 1 (50.0%) and generalized in the other 1 (50.0%). FCDs were either localized or lateralized. Tuber malformation and Focal pachygyria single lesions showed localized semiology. Most encephalomalacia following stroke/trauma showed lateralization 6 (46.2%). CNS inflammations showed two localized and one lateralized semiology. Cysts showed all types of semiology (Table 5). There was a statistically significant association between semiology and sites of epileptiform lesions, as most all lesions' sites showed localized semiology to their respective lesions (Table 6). Lesions that were showed to be localized by interictal EEG were also localized in semiology in 24 (58.5%), but there were 10 (24.4%) and 7 (17.1%) extralesional and generalized, respectively on interictal EEG. Both showed equal lesions with lateralization to lesional hemisphere. Only 4 (44.4%) extralesional interictal EEG was also shown to be extralesional by semiology while 1 (11.1%) was lateralized, 1 (11.1%) generalized, and 3 (33.3%) were normal on interictal EEG. Just 2 (16.7%) were similarly shown to be of broad field in both interictal EEG and semiology, and this was the lowest agreement between the two tests, however, a statistically significant correlation between the two tests was reported as shown in (Table 7). Furthermore, some examples of findings of our patients are demonstrated in (Figures 3,4,and 5)

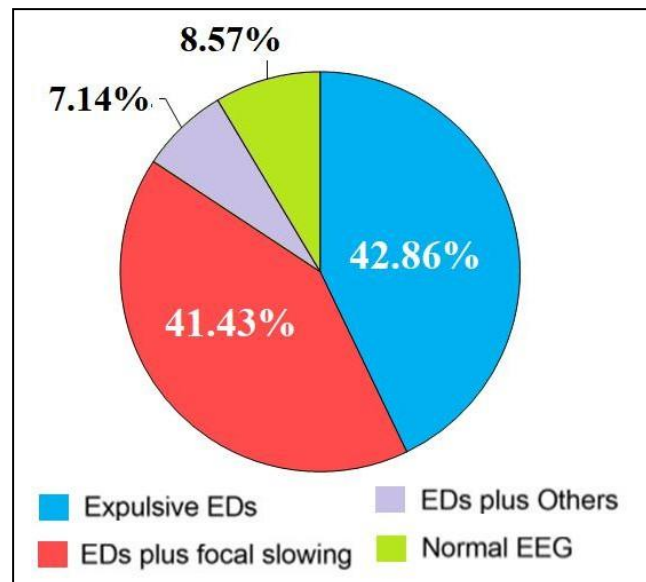


Figure 1: Topographic distribution of the lesions

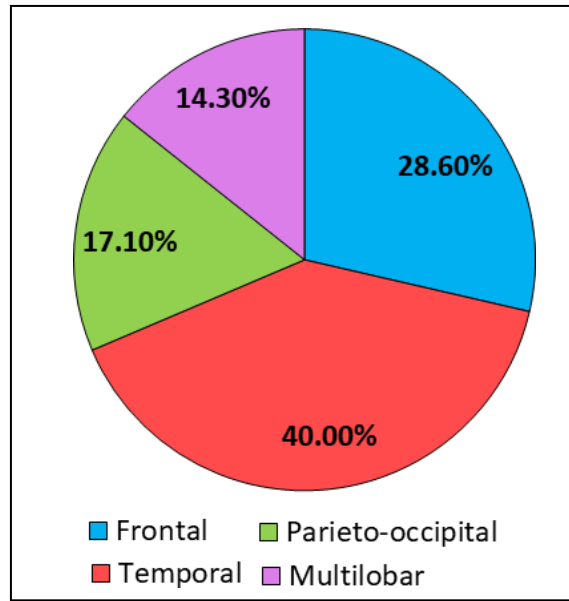


Figure 2: Types of EEG abnormalities

Table 1. Characteristics of epileptiform discharge (n=70)

Variable	Mean	SD
First epileptiform discharge (onset) latency (minute)	6.92	10.51
Frequency of epileptiform discharge (in 1 hour)	165.88	262.8
a) Wakefulness	41.1	81.93
b) Hyperventilation	5.01	12.79
c) IPS	2.4	8.48
d) NREM (stage I and II)	117.17	185.86

Table 2: Correlation of inter-ictal EEG and lesion site by MRI

Interictal EEG	Site of epileptiform lesion				
	Frontal	Temporal	Parieto-occipital	Multilobar	Total
	No.(%)	No.(%)	No.(%)	No.(%)	No.(%)
Localized to lesional lobe	10(50.0)	16(57.1)	1(8.3)	0(0.0)	27(38.6)
Lateralized to lesional hemisphere	0(0.0)	1(3.6%)	2(16.7)	9(90.0)	12(17.1)
Extrasional	2(10.0)	5(17.9)	8(66.7)	0(0.0)	15(21.4)
Localized + extrasional	5(25.0)	5(17.9)	0(0.0)	0(0.0)	10(14.3)
Normal	3(15.0)	1(3.6)	1(8.3)	1(10.1)	6(8.6)
Total	20(28.57)	28(40.0)	12(17.14)	10(14.28)	70(100.0)
P. value < 0.001					

Table 3.Types of brain lesion

Type of lesion	Frequency	%
Hippocampal sclerosis	13	18.5
Tumors	20	28.5
Meningioma	6	30
Glioma	6	30
DNET	5	25
Ganglioglioma	2	10
Lymphoma	1	5
Vascular malformations	9	12.8
Cavernous	7	77.8
AVM	2	22.2
Cortical malformations	4	5.7
FCD	2	50
Tuber	1	25
Focal pachygyria	1	25
Encephalomalacia following stroke/trauma	13	18.6
CNS inflammation	3	4.3
Cysts	8	11.4

Table 4. EEG localization by lesion types

Type of lesion	Localized	Lateralized	Extralesional	Localized+ extralesional	Normal	Total
Hippocampal sclerosis	6	0	3	3	1	13
Meningioma	4	0	0	1	1	6
Glioma	3	0	3	0	0	6
DNET	4	0	0	0	1	5
Ganglioglioma	1	0	1	0	0	2
Lymphoma	0	0	0	1	0	1
Cavernous	3	0	1	1	2	7
AVM	0	0	1	1	0	2
FCD	0	1	1	0	0	2
Tuber malformation	1	0	0	0	0	1
Focal pachygyria	0	0	1	0	0	1
Encephalomalacia following stroke/trauma	2	8	2	0	1	13
CNS inflammation	1	1	1	0	0	3
Cysts	2	1	2	3	0	8
Total	27	12	15	10	6	70

Table 5. Semiologic localization by types of lesion

Type of lesion	Localized	Lateralized	ExtraleSIONal	Generalized	Total
Hippocampal sclerosis	12	0	0	1	13
Meningioma	3	0	0	3	6
Glioma	4	0	1	1	6
DNET	4	0	1	0	5
Ganglioglioma	1	0	1	0	2
Lymphoma	1	0	0	0	1
Cavernous	4	0	2	1	7
AVM	1	0	0	1	2
FCD	1	1	0	0	2
Tuber malformation	1	0	0	0	1
Focal pachygyria	1	0	0	0	1
Encephalomalacia following stroke/trauma	2	6	1	4	13
CNS inflammation	2	1	0	0	3
Cysts	4	0	3	1	8
Total	41	8	9	12	70

Table 6. correlation between seizure semiology and lesion site by MRI

Semiology	Site of epileptiform lesion				
	Frontal	Temporal	Parieto-occipital	Multilobar	Total
	No.(%)	No.(%)	No.(%)	No.(%)	No.(%)
Localized to lesional lobe	11 (55.0)	24 (85.7)	6(50.0)	0(0.0)	41(58.6)
Lateralized to lesional hemisphere	0 (0.0)	0 (0.0)	1 (8.3)	7 (70.0)	8 (11.4)
ExtraleSIONal	3 (15.0)	3 (10.7)	2 (16.7)	1 (10.0)	9 (12.9)
Generalized	6 (30.0)	1 (3.6)	3 (25.0)	2 (20.0)	12 (17.1)
Total	20(28.57)	28(40.0)	12(17.14)	10 (14.28)	70(100.0)
P. value < 0.001					

Table 7. Relationship between semiology and inter-ictal EEG results

Interictal EEG	Semiology				
	Localized to lesional lobe	Lateralized to lesional hemisphere	Extralesional	Generalized	Total
	No.(%)	No.(%)	No.(%)	No.(%)	No.(%)
Localized to lesional lobe	24(34.3)	0(0.0)	0(0.0)	3(4.3)	27(38.6)
Lateralized to lesional hemisphere	0(0.0)	8(11.4)	1(1.4)	3(4.3)	12(17.1)
Extralesional	10(14.3)	0(0.0)	4 (5.7)	1(1.4)	15(21.4)
Localized + extralesional	7(10.0)	0(0.0)	1(1.4)	2(2.9)	10(14.3)
Normal	0(0.0)	0(0.0)	3(4.3)	3(4.3)	6(8.6)
Total	41(58.6)	8(11.4)	9(12.9)	12(17.1)	70(100.0)
Correlation and agreement of semiology with inter-ictal EEG P = 0.357 K = 0.332 Discordance 31/70 (44.3%) Concordance: 39/70 (55.7%) P. value < 0.001 ρ: Spearman's rank-correlation coefficient, k: Cohen's Kappa					

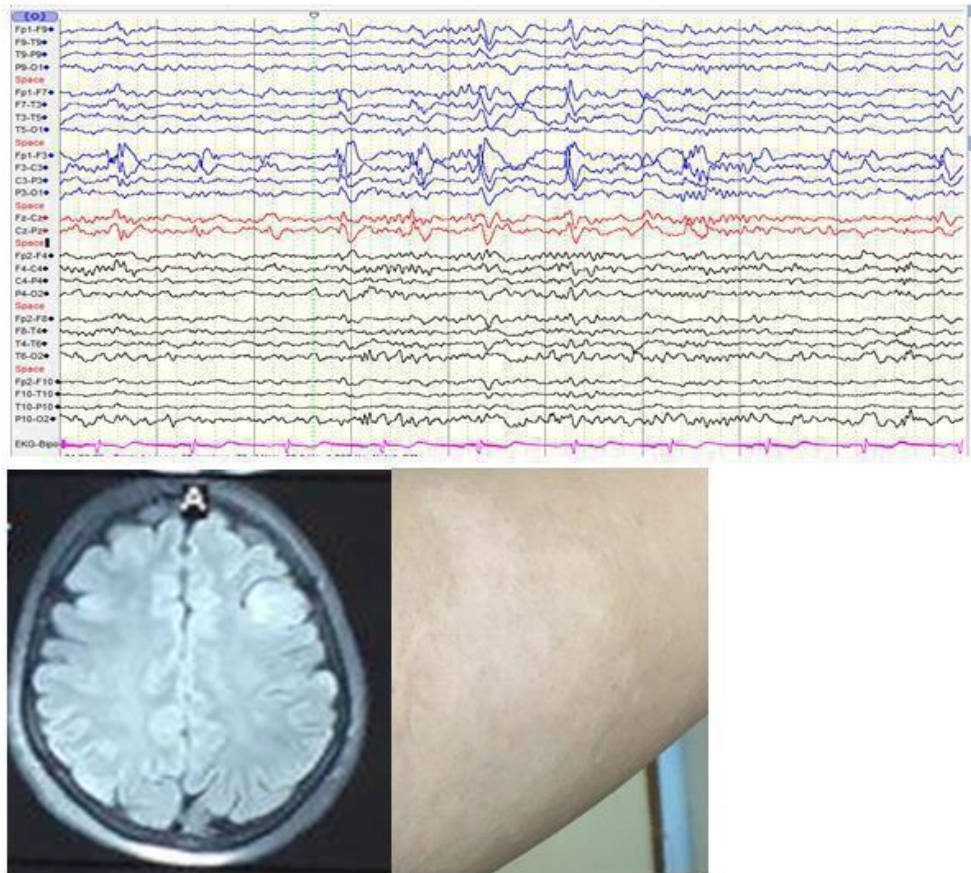


Figure 3. A 30-year old female presented with frequent brief attacks of spacing out with depressive facial expression and versive Rt. sided head and eyes deviation, sometimes ended with GTC seizures. She had ash leaf patches in the back and forearm. Brain MRI (3 Tesla) revealed Lt. lateral middle frontal hyperintense T2 lesion (Tuber). Inter-ictal EEG revealed very frequent SWDs and polyspikes with phase reversal at F3 and F7 (bipolar montage) enhanced during stage II of sleep with preserved sleep architecture.

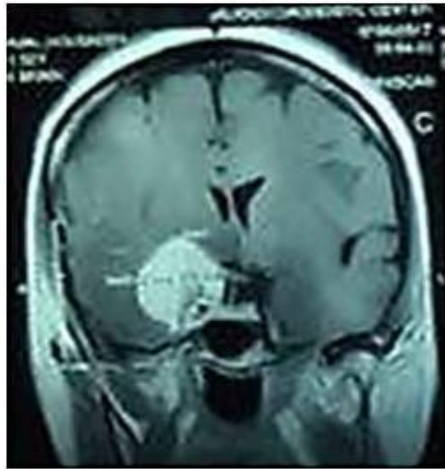
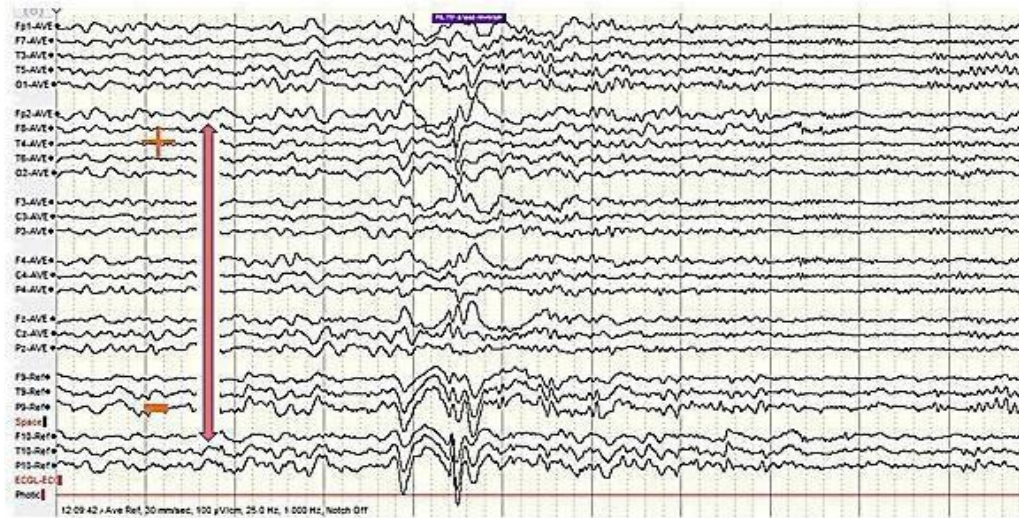


Figure 4. 52-year-old female patient had recurrent attacks of visual illusion in form of macropsia, followed by rising epigastric burning pain with preserved awareness, sometimes ended with GTC seizures. Brain MRI revealed Rt. Basal temporal meningioma of 3*3.5 cm. Inter-ictal EEG revealed intermittent focal polymorphic delta slowing associated with F8, T10, P10 SWDs with phase reversal (longitudinal bipolar montage), referential average montage reveals a radial dipole with negative maxima at T10, P10 and positive maxima at T4.

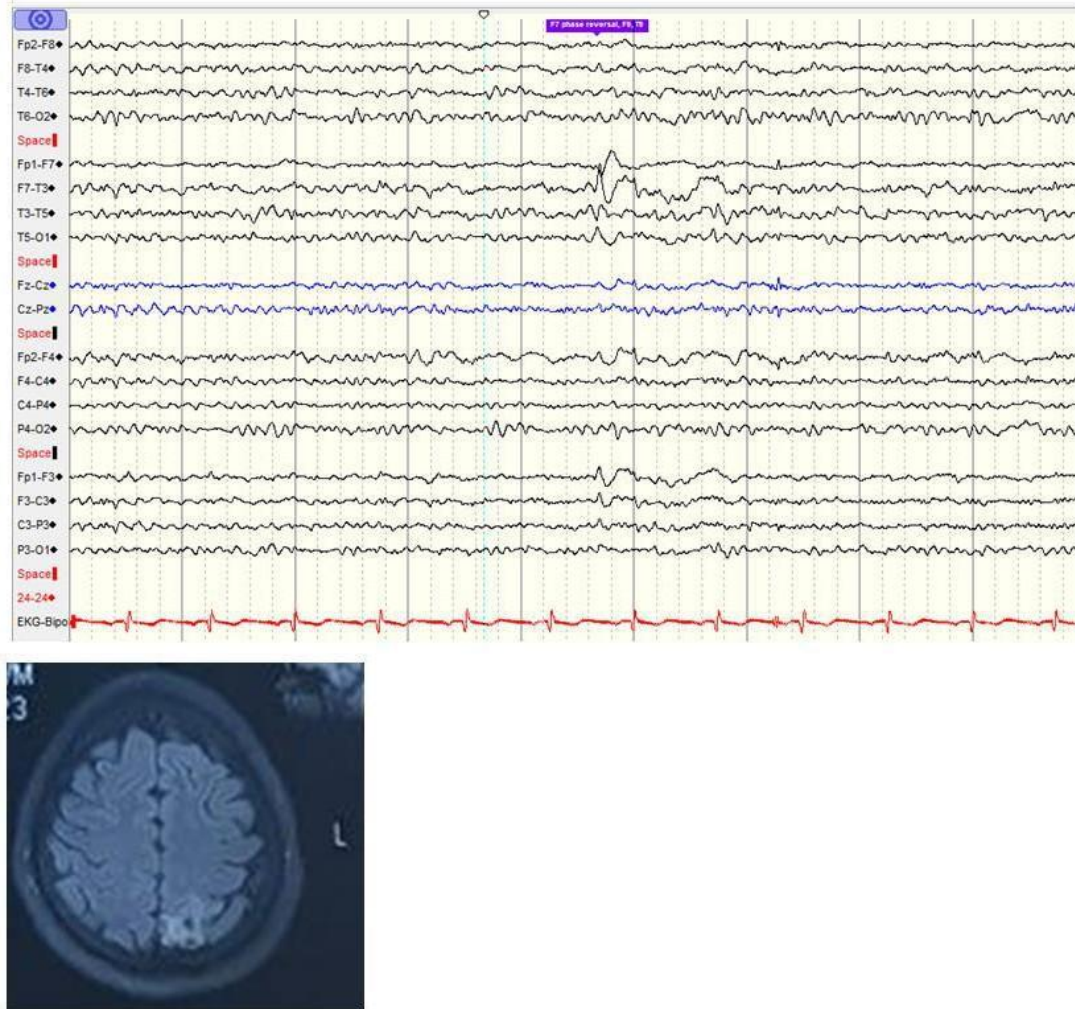


Figure 5. A 27-year-old male patient, complained from frequent brief nocturnal attacks of awakening with frequent spitting, sometimes had unpleasant olfactory hallucination and lip smacking with impaired awareness, infrequently ended with GTC seizures. Brain MRI revealed Lt. Parietal Glioma. Inter-ictal EEG demonstrated frequent SWDs with phase reversal at F7 and preserved background. Both semiology and inter-ictal EEG suggesting TLE which was discordant with MRI lesion localization.

4. DISCUSSION

Our study demonstrates that the occurrence and localization of inter-ictal epileptiform discharges differ according to the site and type of the lesions. We have also encountered two distractions in inter-ictal EEG recording: the presence of discharges outside the site of the lesions and normal EEG. The results are suspected from knowing the natural architecture of each lobe, with the temporal lobe is known to have well defined borders and connections in between and with its sub-structures. However, mesial temporal structures and that adjacent or involving the insula, found to have connections with frontal lobe, which may explain its potential to have extratemporal seizure and EEG manifestations. (50-53) While frontal lobes and because of their larger size, massive connections between both hemispheres and have mesial and orbitofrontal regions that are not accessible to scalp EEG, unless being propagated to superficial regions, then it's common to find a high proportion of FLE with mis-localized IEDs. (54,55). However, in this study; one half (50%) of FL lesions were well localized. This may be due to the site of lesions as those located at the convexities are more localizing than mesial lesions, other factors may include, the diversity of patients' ages rather than for example choosing children exclusively as children are found to have diffused and mis-localized EDs more than adults. (56). Also the age of the lesions can play a role, that being older, increases the possibility of having more impact on its environment with buildup of new synapses and connections. (54,57). Parieto-occipital lobes have poorly defined boundaries and extensive connections with other lobes. Occipital lobes connect to temporal lobes through inferior longitudinal fasciculus or indirectly through polysynaptic U fibers. (58) Therefore, rendering their scalp EEG less localizing with high proportion of extra-lesional EEG manifestations. The findings of present study agree to a large extent with the above concept and because of their convergent architecture, they have been considered as one group as many authors did. (59,60). Despite the short term of recording inter-ictal EEG, the study demonstrated results relatively comparable to a previous study conducted in the period from 1991-2009 including 997 patients with diverse pathologies, which have utilized long term VEEG monitoring for the same purpose but with exclusion of multilobar lesions.(61) It also agree with another study conducted in the period from 1994-2010 comprising 63 patients with same methodology as that mentioned above but included multilobar lesions of variable pathologies. (62)

Multilobar lesions have been included in the present study to have a complete picture about all possible lesional localization. In the previous mentioned studies, Temporal lobe lesions were localized in (58.6%), frontal lobe with (27.5%) and P/O lobe with (12.1%), multilobar lesions were lateralized in (43%) while exclusively extralesional in temporal lobe lesions with (2.3%), frontal lesions (23.2%), P/O (48.5%). Using sleep deprivation as a provocation method may be one of the explanations beyond such convergence in results, means SDEEG can buffer the property of long term monitoring (63). The above concept had further demonstrated previously in a study conducted in 1992-1995 included 90 cases of temporal lobe epilepsies which used an approach nearly similar to ours with SDEEG record lasted for 2 hours' duration. They found a concordance rate of (61%) between MRI and IEEG localization. (64). In the present study, the frequency of EDs during NREM sleep was greater than wakefulness, HV and IPS. This finding may be related to the potentiating effect of sleep. However, its known that HV and IPS had less effect on focal than generalized EDs. (44,45,65) Our study agreed with that. However, the onset of first EDs was earlier than commencement of sleep in some of the cases with a median of 6.92 minutes, at about the beginning of hyperventilation according to our study's protocol. This may be related to seizure frequencies, type of epilepsy being structural one and the fact that SDEEG activation is already present during the waking phase as supported by previous studies. (66,67,68). In addition to SD, the type of predominant lesion and its location may play a role in localization. For that reason, we had investigated the types of the lesions and their lobar location in addition to their relation to inter-ictal EEG. It was clear from the results that most of the lesions (52.9%) are well localized to their sites. Most of them having produced focal slowing (49%), indicating their destructive nature which can be predicted by the prevalence of the lesions, including brain tumors, vascular insults and CNS inflammations collectively (with known aggressive nature). Supporting their role in epileptogenesis as a symptomatic cause rather than accidental findings. (16,17,18,19,20). One of the distractions in our study is the presence of epileptiform activity at a distance from lesional site. In fact, this is not the first study to demonstrate such a finding and this subject became a field of extensive researches nowadays. There are several explanations for that. First, brain lesions may produce changes in their surrounding environment, in their borders or may be similar areas of contralateral hemisphere, in form of "ischemia, edema,

local neuronal injuries (synaptic), electrical and biochemical changes”, making them prone to be epileptogenic as proved by histopathological studies. (1,2) Second, the fact that brain areas are interconnected in networks, these networks can provide low seizure threshold pathways through which seizures can spread. In the inter-ictal periods, these pathways may manifest by demonstrating EDs. In another word, this may support the hypothesis of potential epileptogenic areas, means that there are silent cerebral foci with low seizure threshold which may produce seizures at any times. This has been widely accepted, especially with the proved findings that extended surgical excision of areas outside the lesional site resulting in more favorable prognosis regarding post-operative seizure freedom than excisions limited to lesion removal (1,2,4,69,70) . Third, family history of epilepsy may influence EEG findings of patients with symptomatic focal epilepsies and even found to have less likely to be seizure free post-operatively (2,71). To investigate the third possibility, it was necessary to evaluate those patients with family history of epilepsy for the distribution of EDs in their EEGs, 55.6 % of those with positive FHE have EDs extended beyond their MRI lesions. This may support previous studies concerned with the influence of FH on EEG of patients with symptomatic focal epilepsies (71), however; being a true association or coincidental findings may require further studies. The other distraction is the presence of normal EEGs. This may be related to EEG factors, as short time of recording despite provocation methods, or lesion factors as their deep or sulcal locations, small sized epileptogenic lesions that couldn’t be detected by EEG (< 10 cm²), the direction of dipoles, e.g. horizontal to cortical surface rather than radial rendering the EEG unable to detect them (2,18,28,29). In order for seizures to manifest, there should be a strong enough electrical activity to cross an “eloquent cortex”. (2,70) Therefore, it is proposed that the “symptomotogenic zones” and “seizure onset zones” need to intersect at time of seizure manifestation and ictal EEG changes. This had been supported by previous study in TLE combining semiologic and ictal EEG findings which was found to have boosted the localization value when being combined with a concordance rate at around 90%. (72) The “symptomotogenic zone”, may or may not intersect with that of “irritative zone”, as the latter not necessarily represent active epileptogenic areas, therefore; both may have different pathways. (2,70) How often inter-ictal EEG correlate with seizures semiology was investigated in our study. The initial rather than propagating symptoms were selected and

classified accordingly and found to have reliable localizing and lateralizing values as compared with the literature. (23,73) Inter-ictal EEG (52.9%) was slightly less localizing than semiology (58.6%) but with same lobar distribution, also they have same relation to lesion type, means that same mechanisms may work like in relation with inter-ictal EEG. When considering the fact that it's one EEG record, while seizure semiology reflects a history of many seizures having same description or may be more than one manifestation, in addition to the relative short duration of EEG record. Then, we may be able to explain that minor difference. By combining the above semiologic and inter-ictal EEG localization, there was 44.4% localizing value (including the category of localized + extralesional in inter-ictal EEG). Although, it was lower than IIEEG alone and semiology alone, it seems reliable because as mentioned above, “irritative zone” is larger than seizure onset and “symptomotogenic zones”, and may include areas of “potential epileptogenicity” that do not involve same route of seizure origin and spread but may manifest with seizures in future. Therefore, irritative zone need not to intersect with symptomotogenic one to manifest in EEG, however; it reflects both ongoing and potential epileptogenic areas of brain. On the other hand, seizure symptoms and ictal EEG would largely reflect same pathways which represent ongoing epileptogenic areas. This concept has recently supported by increased success rates of epilepsy surgeries when lesionectomies had extended to include these areas containing inter-ictal EDs rather than restricted to seizure onset or symptomotogenic zones (2,4,28,74). The overall concordance (agreement) between semiology and IIEEG was 55.7 %. Restricted selection of the initial symptoms rather than the whole semiologic picture, which can track the highly excitable pathway; may be one of the reasons of discordance in addition to the differences in concept of both zones.

5. CONCLUSIONS

We conclude that Basic level inter-ictal EEG with partial sleep deprivation can be used in localization and tracking of epileptogenic pathways, and the concept of being discordant from semiology should have a crucial attention, as previously suggested that the irritative zone correlate more accurately with epileptogenic zone. However, the localizing value can be increased by combining inter-ictal EEG with semiology in lesional epilepsies. Therefore, we recommended that further studies to be conducted for further assessment and evaluation

Ethical Clearance: Ethical clearance and approval of the study are ascertained by the authors. All ethical issues and data collection were in accordance with the World Medical Association Declaration of Helsinki 2013 for ethical issues of researches involving humans, informed consent obtained from all patients. Data and privacy of patients were kept confidentially.

Conflict of interest: Authors declared none

Funding: None, self-funded by the authors

REFERENCES

1. Rosenow F, Lüders H. *Presurgical evaluation of epilepsy. Brain.* 2001; 124 (Pt 9):1683–700.
2. Palmieri A. *The concept of the epileptogenic zone: a modern look at Penfield and Jasper's views on the role of interictal spikes. Epileptic Disord.* 2006; 8 (Suppl.2): S10-5.
3. Rosenow F, Lüders H. *Presurgical assessment of the epilepsies with clinical neurophysiology and functional imaging. Amsterdam. Elsevier B.V; (Vol 3), 2004.*
4. Hebbink J, Meijer H, Huiskamp G, et al. *Phenomenological network models: Lessons for epilepsy surgery. Epilepsia.* 2017; 58(10):e147-e151.
5. Pillai J, Sperling MR. *Interictal EEG and the diagnosis of epilepsy. Epilepsia.* 2006;47(Suppl. 1):14-22.
6. Fisher RS, Acevedo C, Arzimanoglou A, et al. *A practical clinical definition of epilepsy. Epilepsia.* 2014; 55(4):475–482.
7. Fisher RS, van Emde Boas W, Blume W, et al. *Epileptic seizures and epilepsy: definitions proposed by the International League Against Epilepsy (ILAE) and the International Bureau for Epilepsy (IBE). Epilepsia.* 2005; 46:470–472.
8. Fisher RS, Cross JH, French JA, et al. *Operational classification of seizure types by the International League Against Epilepsy: Position Paper of the ILAE Commission for Classification and Terminology. Epilepsia.* 2017; 58(4):522–530.
9. Berg AT, Berkovic SF, Brodi MJ, et al. *Revised terminology and concepts for organization of seizures and epilepsies: Report of the ILAE Commission on Classification and Terminology, (2005-2009) Epilepsia.* 2013; 51(4):676-6.
10. Loddenkemper T, Kellinghaus C, Wyllie E, et al. *A proposal for a five-dimensional patient-oriented epilepsy classification. Epileptic Disord.* 2005; 7:308-20.
11. Scheffer IE, Berkovic S, Capovilla G, et al. *ILAE classification of the epilepsies: position paper of the ILAE Commission for Classification and Terminology. Epilepsia.* 2006; 58,512–521.
12. Engel JJr. *A proposed diagnostic scheme for people with epileptic seizures and with epilepsy: Report of the ILAE Task Force on Classification and Terminology. Epilepsia.* 2001; 42:796–803.
13. Engel JJr. *Report of the ILAE Classification Core Group. Epilepsia.* 2006; 47:1558–68.
14. Panayiotopoulos CP. *A Clinical Guide to Epileptic Syndromes and their Treatment. Revised Second Edition. ISBN: 978-1-84996-160-8. Springer Healthcare Ltd 2010. Page 435*

15. Shorvon SD. *The etiologic classification of epilepsy. Epilepsia. 2011; 52(6):1052–1057.*
16. Degen R, Ebner A, Lahl R, et al. *Various findings in surgically treated epilepsy patients with dysembryoplastic neuroepithelial tumors in comparison with those of patients with other low-grade brain tumors and other neuronal migration disorders. Epilepsia. 2002;43(11):1379–1384.*
17. Tyvaert L, Hawco C, Kobayashi E, et al. *Different structures involved during ictal and interictal epileptic activity in malformations of cortical development: an EEG-fMRI study. Brain. 2008; 131: 2042-2060.*
18. Sharanreddy M, Kulkarni PK. *Can EEG test help in identifying brain tumor? . Int J Health Med Eng. 2013; 7(11):*
19. Bhattarai S, Xiao-ning Z, Tuerxun T. *EEG and SPECT changes in acute ischemic stroke. J Neurol Neurophysiol. 2014; 5:2.*
20. Murthy JMK. *Intracranial arachnoid cysts: Epileptic seizures. Neurol India. 2013; 61(4).Page : 343-344*
21. Noachtar S. *Epilepsy: seizure semiology. Rivista di Neuroradiologia. 2004; 17: 464-471.*
22. Seneviratne U, Rajendran D, Brusco M, et al. *How good are we at diagnosing seizures based on semiology? Epilepsia. 2012; 53:e63–e66.*
23. Lüders HO. *Textbook of Epilepsy Surgery. 2008. page, 428, 440, 463, 464.*
24. Tufenkjian K, Lüders HO. *Seizure semiology: its value and limitations in localizing the epileptogenic zone. J Clin Neurol. 2012; 8:243-250.*
25. Niedermeyer E, da Silva FL. *Electroencephalography: basic principles, clinical applications, and related fields. Lippincott Williams & Wilkins. 2004.*
26. Fernández-Torre JL. *Interictal EEG. Springer-Verlag London Limited 2010.*
27. Dworetzky BA, Reinsberger C. *The role of the interictal EEG in selecting candidates for respective epilepsy surgery. Epilep Behav. 2011; 20:167–171.*
28. Marsh ED, Peltzer B, Brown MW, et al. *Interictal EEG spikes identify the region of electrographic seizure onset in some, but not all, pediatric epilepsy patients. Epilepsia. 2010; 51(4):592–601.*
29. Koukou A, Dupont S, Szurhaj W, et al. *Complete change of seizure and spike lateralization in temporal lobe epilepsy at two separate monitoring. Clin Neurophysiol. 2007; 118:255–261.*
30. Tao JX, Ray A, Hawes-Ebersole S, et al. *Intracranial EEG Substrates of Scalp EEG Interictal Spikes. Epilepsia. 2005; 46(5):669–676.*
31. Spencer SS, Sperling MR, Shewmon DA, et al. *Intracranial electrodes. In: Engel Jr J, Pedley TA, editors. Epilepsy: a comprehensive textbook. 2nd ed. Philadelphia: Lippincott Williams & Williams; 2008. p. 1791–815.*
32. Stern JM. *Interictal epileptiform patterns. In: Atlas of EEG patterns. Wolters Kluwer. 2013; p. 249-250.*
33. Markand ON. *Pearls, perils, and pitfalls in the use of the electroencephalogram. Sem Neurol. 2003; 23(1):7-46.*
34. Laoprasert P. *Atlas of pediatric EEG. McGraw-Hill Companies Inc.; USA (2011): page 690.*
35. Koutroumanidis M, Arzimanoglou A, Caraballo R, et al. *The role of EEG in the diagnosis and*

- classification of the epilepsy syndromes: a tool for clinical practice by the ILAE Neurophysiology Task Force (Part1). Epileptic Disord.* 2017; 19(3):233-98.
36. Brenner M. Increasing the yield of EEG. *J Clin Neurophysiol.* 2006; 23:282–293.
 37. S SEDDIGH, F THÖMKE, TH VOGT, Complex partial seizures provoked by photic stimulation. *J Neurol Neurosurg Psychiatry* 1999; 66:801–808.
 38. Kleina KM, Knakea S, Hamera HM, et al. Sleep but not hyperventilation increases the sensitivity of the EEG in patients with temporal lobe epilepsy. *Epilepsy Res.* 2003; 56:43–49.
 39. Gaillard WD, Cross JH, Duncan JS, et al. Epilepsy imaging study guideline criteria: commentary on diagnostic testing study guidelines and practice parameters. *Epilepsia.* 2011; 52(9):1750–1756.
 40. Wellmer J, Quesada CM, Rothe L, et al. Proposal for a magnetic resonance imaging protocol for the detection of epileptogenic lesions at early outpatient stages. *Epilepsia.* 2013; 54:1977–1987.
 41. Acharya JN, Hani A, Cheek J, et al. American Clinical Neurophysiology Society Guideline 2: Guidelines for Standard Electrode Position Nomenclature. *J Clin Neurophysiol.* 2016; 33:308–311.
 42. Sinha SR, Sullivan L, Sabau D, et al. American Clinical Neurophysiology Society Guideline 1: Minimum Technical Requirements for Performing Clinical Electroencephalography. *J Clin Neurophysiol.* 2016; 33:303–307.
 43. Kasteleijn-Nolst Trenité DGA, Rubboli, G, Hirsch E, et al. Methodology of photic stimulation revisited: Updated European algorithm for visual stimulation in the EEG laboratory. *Epilepsia.* 2012; 53(1):16-24.
 44. Gilbert DL, De Roos S, Bare MA. Does sleep or sleep deprivation increase epileptiform discharges in pediatric electroencephalograms? *Pediatrics.* 2004; 114(3).
 45. Giorgi FS, Maestri M, Guida M, et al. Controversial issues on EEG after sleep deprivation for the diagnosis of epilepsy. *Epilepsy Res Tret.* 2013; Article ID 614685,5 pages.
 46. Guaranha MS, Garzon E, Buchpiguel CA, et al. Hyperventilation Revisited: physiological effects and efficacy on focal seizure activation in the era of video-EEG monitoring *Epilepsia.* 2005; 46(1):69–75.
 47. Acharya JN, Hani AJ, Thirumala PD, et al. A Proposal for Standard Montages to Be Used in Clinical EEG. *J Clin Neurophysiol.* 2016; 33:312–316.
 48. Sandra Rose and John S. Ebersole. Advances in spike localization with EEG dipole modeling. *Clinical EEG and Neuroscience.* 2009 vol. 40 no. 4.
 49. Foldvary N., Klem G., Hammel J., et al. The localizing value of ictal EEG in focal epilepsy. *Neurology* 2001;57: 2022–2028
 50. Selvitelli MF, Walker LM, Schomer DL, et al. The relationship of interictal epileptiform discharges to clinical epilepsy severity: A study of routine EEGs and review of the literature. *J Clin Neurophysiol.* 2010; 27(2): 87–92.
 51. Abadia Jr, Bell W, Keyes Jr, et al. Assessment and cost comparison of sleep-deprived EEG, MRI and PET in the prediction of surgical treatment for epilepsy. *Seizure.* 2002; 11:303–309.
 52. Lüders HO, Noachtar S. *Epileptic Seizures – Pathophysiology and Clinical Semiology.* New York:

Churchill Livingstone, 2000.

53. Isnard J, Guenot M, Sindou M, et al. Clinical manifestations of insular lobe seizures: a stereo-electroencephalographic study. *Epilepsia*. 2004; 45:1079–1090
54. Vadlamudi L, SoI EL, Worrell GA, et al. Factors underlying scalp-EEG interictal epileptiform discharges in intractable frontal lobe epilepsy. *Epileptic Disord*. 2004; 6:89-95.
55. Shihabuddin B, Abou-Khalil B, Delbeke D, et al. Orbitofrontal epilepsy masquerading as temporal lobe epilepsy-a case report. *Seizure*. 2001; 10:134–138.
56. Lawson JA, Cook MJ, Vogrin S, et al. Clinical, EEG and quantitative MRI differences in pediatric frontal and temporal lobe epilepsy. *Neurology*. 2002; 58:723-9
57. Holmes MD, Kutsy RL, Ojemann GA, et al. Interictal, unifocal spikes in refractory extratemporal epilepsy predict ictal origin and postsurgical outcome. *Clin Neurophysiol*. 2000; 111:1802-8.58. Catani M, Jones DK, Donato R, et al. Occipito-temporal connections in the human brain. *Brain*. 2003; 126:2093–2107.
59. Dalmagro CL, Bianchin MM, Velasco TR, et al. Clinical features of patients with posterior cortex epilepsies and predictors of surgical outcome. *Epilepsia*. 2005; 46:1442–9.
60. Yu T, Wang Y, Zhang G, et al. Posterior cortex epilepsy: Diagnostic considerations and surgical outcome. *Seizure*. 2009; 18:288–292.
61. Re´mi J, Vollmar C, de Marinis A, et al. Congruence and discrepancy of interictal and ictal EEG with MRI lesions in focal epilepsies. *Neurology*. 2011; 77:1383–1390.
62. Sarkis RA, Jehi L, Najm IM, et al. Seizure outcomes following multilobar epilepsy surgery. *Epilepsia*. 2012; 53(1):44–50.
63. De Roos ST, Chillag KL, Keeler M, et al. Effects of sleep deprivation on the pediatric electroencephalogram. *Pediatrics*. 2009; 123(2):703–708.
64. Gilliam F, Bowling S, Bilir E, et al. Association of combined MRI, interictal EEG, and ictal EEG results with outcome and pathology after temporal lobectomy. *Epilepsia*. 1997; 38(12):1315-1320.
65. Leach JP, Stephen LJ, Salveta C, et al. Which electroencephalography (EEG) for epilepsy? The relative usefulness of different EEG protocols in patients with possible epilepsy. *J Neurol Neurosurg Psychiatry*. 2006; 77(9):1040–1042.
66. Losey TE, Uber-Zak L. Time to first interictal epileptiform discharge in extended recording EEGs. *J Clin Neurophysiol*. 2008; 25:357–360.
67. Werhahna KJ, Hartlb E, Hamanna K, et al. Latency of interictal epileptiform discharges in long-term EEG recordings in epilepsy patients. *Seizure*. 2015; 29:20–25.
68. Narayanan JT, Labara DR, Schaul N. Latency to first spike in the EEG of epilepsy patients. *Seizure*. 2008; 17:34-41.
69. Paglioli E, Palmi A, Paglioli E, et al. Survival analysis of the surgical outcome of temporal lobe epilepsy due to hippocampal sclerosis. *Epilepsia*. 2004; 45:1383-9.
70. Lüders HO, Najm I, Nair D, et al. The epileptogenic zone: general principles. *Epileptic Disord*. 2006;

8(Suppl.2):S1-9.

71. Babbain FA. *Impact of a family history of epilepsy on the diagnosis of epilepsy in southern Saudi Arabia. Seizure.* 2013; 22:542–547.
72. Serles W, Caramanos Z, Lindinger G, et al. *Combining ictal surfaceelectroencephalography and seizure semiology improves patient lateralization in temporal lobe epilepsy. Epilepsia.* 2000; 41(12):1567–1573.
73. Asadi-Pooya AA. *Lateralizing and localizing findings in focal epilepsies: A concise review. J Neurol Neurophysiol* 2012, S2.
74. Krsek P, Maton B, Jayakar P, et al. *Incomplete resection of focal cortical dysplasia is the main predictor of poor postsurgical outcome. Neurology.* 2009 Jan 20;72(3):217-23